

## Review Article

# Thyroid ultrasound

Vikas Chaudhary, Shahina Bano<sup>1</sup>

Department of Radiodiagnosis, Employees' State Insurance Corporation Model Hospital, Gurgaon, Haryana,

<sup>1</sup>Department of Radiodiagnosis, Lady Hardinge Medical College and Associated Smt. Sucheta Kriplani and Kalawati Hospitals, New Delhi, India

### ABSTRACT

Thyroid ultrasonography has established itself as a popular and useful tool in the evaluation and management of thyroid disorders. Advanced ultrasound techniques in thyroid imaging have not only fascinated the radiologists but also attracted the surgeons and endocrinologists who are using these techniques in their daily clinical and operative practice. This review provides an overview of indications for ultrasound in various thyroid diseases, describes characteristic ultrasound findings in these diseases, and illustrates major diagnostic pitfalls of thyroid ultrasound.

**Key words:** Color doppler, high resolution ultrasonography, thyroid, ultrasound, ultrasound elastography

## INTRODUCTION

High-resolution ultrasonography (USG) is the most sensitive imaging modality available for examination of the thyroid gland and associated abnormalities. Ultrasound scanning is non-invasive, widely available, less expensive, and does not use any ionizing radiation. Further, real time ultrasound imaging helps to guide diagnostic and therapeutic interventional procedures in cases of thyroid disease. The major limitation of ultrasound in thyroid imaging is that it cannot determine thyroid function, i.e., whether the thyroid gland is underactive, overactive or normal in function; for which a blood test or radioactive isotope uptake test is generally required.<sup>[1,2]</sup>

## INDICATIONS OF THYROID ULTRASOUND

Indications for thyroid USG, following the American Association of Clinical Endocrinologists (AACE) and Associazione Medici Endocrinologi (AME) recommendations,<sup>[3]</sup> are as follows:

1. To confirm presence of a thyroid nodule when physical examination is equivocal.
2. To characterize a thyroid nodule(s), i.e. to measure the dimensions accurately and to identify internal structure and vascularization.
3. To differentiate between benign and malignant thyroid masses, based on their sonographic appearance.
4. To differentiate between thyroid nodules and other cervical masses like lymphadenopathy, thyroglossal cyst and cystic hygroma.
5. To evaluate diffuse changes in thyroid parenchyma.
6. To detect post-operative residual or recurrent tumor in thyroid bed or metastases to neck lymph nodes.
7. To screen high risk patients for thyroid malignancy like patients with history of familial thyroid cancer, multiple endocrine neoplasia (MEN) type II and irradiated neck in childhood.
8. To guide diagnostic (FNA cytology/biopsy) and therapeutic interventional procedures.

## ULTRASOUND EXAMINATION TECHNIQUE

All patients are examined in supine position with hyperextended neck, using a high frequency linear-array transducer (7-15 MHz) that provides adequate penetration and high resolution image. Scanning is done both in transverse and longitudinal planes. Real time imaging of thyroid lesions is performed using both gray-scale and color Doppler techniques. The imaging characteristics of

### Access this article online

#### Quick Response Code:



Website:  
[www.ijem.in](http://www.ijem.in)

DOI:  
10.4103/2230-8210.109667

**Corresponding Author:** Dr. Vikas Chaudhary, Department of Radiodiagnosis, Employees' State Insurance Corporation Model Hospital, Gurgaon - 122 001, Haryana, India. E-mail: [dr\\_vikaschaudhary@yahoo.com](mailto:dr_vikaschaudhary@yahoo.com)

a mass (viz. location, size, shape, margins, echogenicity, contents and vascular pattern) should be identified. Fine needle aspiration (FNA) biopsy should be suggested to the referring physician if required.<sup>[4,5]</sup>

## NORMAL ANATOMY

The normal thyroid gland [Figure 1a] consists of two lobes and a bridging isthmus. Thyroid size, shape and volume varies with age and sex. Normal thyroid lobe dimensions are: 18-20 mm longitudinal and 8-9 mm antero-posterior (AP) diameter in newborn; 25 mm longitudinal and 12-15 mm AP diameter at one year age; and 40-60 mm longitudinal and 13-18 mm AP diameter in adult population. The limits of normal thyroid volume (excluding isthmus, unless its thickness is >3 mm) are 10-15 ml for females and 12-18 ml for males. The relationships with surrounding structures are: sterno-cleido-mastoid and strap muscles anteriorly; trachea/esophagus and longus colli muscles posteriorly; and common carotid arteries and jugular veins bilaterally.<sup>[6]</sup>

Color and power Doppler ultrasound (US) are useful to evaluate vascularity of the thyroid gland and focal masses. Thyroid gland is a highly vascular structure supplied by superior and inferior thyroid arteries. The thyroid arteries can be visualized on color Doppler examination [Figure 1b], while the flow parameters from these vessels can be measured by spectral Doppler examination. Normally, a low resistance flow with high peak systolic velocity (PSV) is detected in these vessels on spectral Doppler analysis [Figure 1c]. The normal PSV in intra thyroid arteries ranges between 15-30 cm/second, but it can rise in certain pathologies (like Graves' disease) to over 100 cm/sec.<sup>[6]</sup>

## CONGENITAL AND DEVELOPMENTAL ANOMALIES OF THYROID GLAND

The thyroid gland primordium develops from median eminence in the floor of primitive pharynx (a point later known as foramen cecum at the base of tongue) during 4<sup>th</sup> week of gestation. From foramen cecum, the primitive primordium descends through anterior midline portion of the neck to reach its final position below thyroid cartilage by 7<sup>th</sup> week of gestation. During this descent, the developing thyroid gland retains an attachment to the pharynx by a narrow epithelial stalk known as thyroglossal duct. This duct usually becomes obliterated by 8<sup>th</sup>-10<sup>th</sup> week of gestation. Thyroid hormone synthesis normally begins at about 11<sup>th</sup> week of gestation.<sup>[7-9]</sup>

Occasionally, rests of thyroid tissue may remain along the course of thyroglossal duct, giving rise to an additional thyroid lobe, the pyramidal lobe, attached to distal end of

the thyroglossal duct and left side of isthmus (seen in 50% of population). Persistence of thyroglossal duct results in formation of thyroglossal cyst [Figure 2], which clinically presents as midline neck swelling or lump, usually found at level of hyoid bone or thyroid cartilage. On ultrasound, the cyst appears as a well-defined anechoic to hypoechoic lesion with posterior acoustic enhancement. Internal echoes may be seen within the cyst due to hemorrhage or infection. Ectopic thyroid represents an arrest in usual descent of part or all of the thyroid tissue along the normal pathway. Ectopic thyroid gland develops most commonly at sublingual (midline at foramen cecum), suprahyoid or infrahyoid position. USG shows presence of an ectopic thyroid tissue and the normal thyroid gland may or may not be present at normal position. Ectopic thyroid may be easily detected on CT and radionuclide scans. Congenital agenesis or hypoplasia (unilobar type or of isthmus) of the thyroid gland may occur due to developmental failure of all or part of thyroid gland. On USG, agenesis of isthmus is characterized by absence of isthmus with the lateral lobes positioned independently on either side of the trachea.<sup>[7-9]</sup>

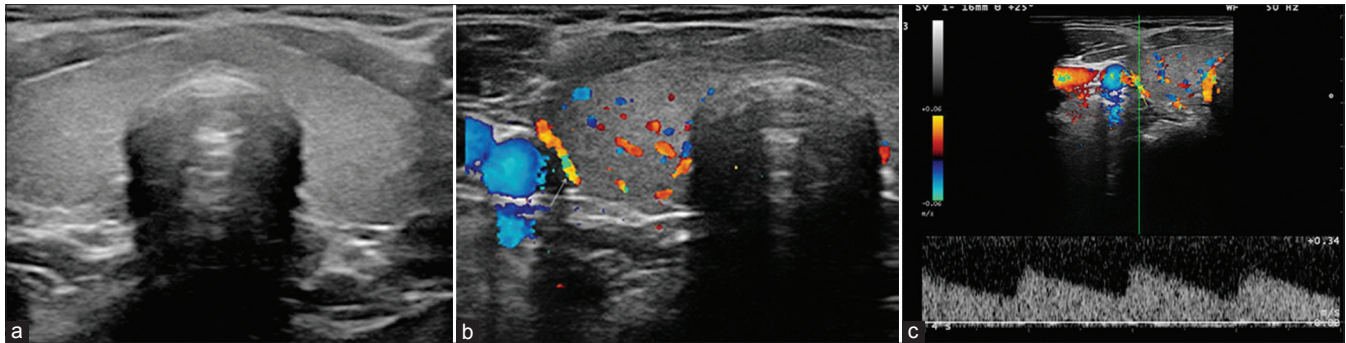
## DISEASES OF THYROID GLAND

The incidence of all thyroid diseases is higher in females than in males. Nodular thyroid disease is the most common cause of thyroid enlargement. Majority of patients with thyroid disease present with midline neck swelling, occasionally causing dysphagia and hoarseness of voice. Broadly the thyroid diseases are classified into three categories: (i) benign thyroid masses, (ii) malignant tumors of thyroid gland, and (iii) diffuse thyroid enlargement.<sup>[1]</sup>

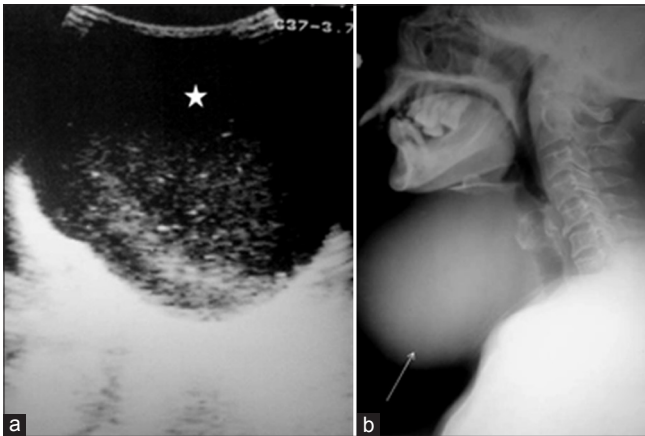
## THYROID NODULE(S)

Nodularity within thyroid is the norm. The incidence and development of nodules correlate directly with age of the patient and is regarded as a part of normal maturation process of the thyroid gland. The incidence of thyroid nodules is very high on USG, ranging from 50% to 70%. Thyroid cancer accounts for less than 7% cases.<sup>[5,10]</sup> Although there is some overlap between ultrasound appearance of benign and malignant nodules, certain USG features are helpful in differentiating the two.

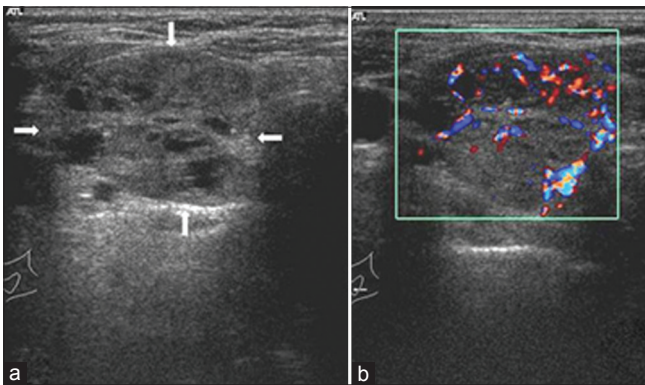
The most common cause of benign thyroid nodule is nodular hyperplasia. Thyroid adenomas are other common benign neoplasms of thyroid that are mostly solitary but may also develop as a part of multinodular masses. Iso- or hyper-echogenicity of the thyroid nodule in conjunction with a spongiform appearance is the most reliable criterion for benignity of the nodule on gray-scale ultrasound [Figures 3 and 4]. Other features like nodule



**Figure 1:** Normal thyroid gland. (a) Gray scale ultrasound, transverse scan showing normal thyroid anatomy, (b) Arterial vascularization of the thyroid gland. On color Doppler, the inferior thyroid artery (arrow) is seen, (c) Blood flow pattern in normal thyroid gland. On spectral display, a low resistance flow with a high peak systolic velocity is obtained

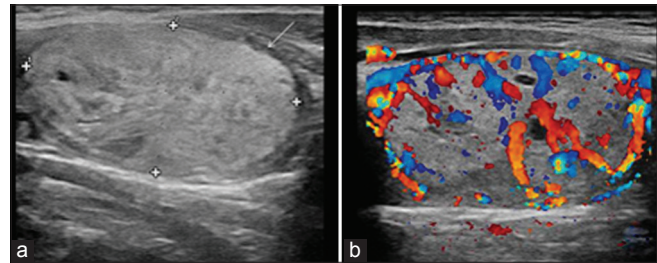


**Figure 2:** Thyroglossal cyst in a patient who presented with midline neck swelling. Ultrasound neck (a) shows a well-defined anechoic cystic lesion with multiple low level internal echoes (asterisk) and posterior acoustic enhancement. Multiple low level internal echoes within the cyst may be due to hemorrhage or infection. X-ray neck lateral view (b) of the same patient shows large, soft tissue/cystic midline swelling (white arrow)



**Figure 4:** Follicular adenoma thyroid in a 40-year-old female patient. Transverse gray-scale ultrasound neck (a) shows a large well circumscribed heterogeneous thyroid nodule with multiple internal cystic spaces giving characteristic "spongiform appearance" to the lesion. Color Doppler sonogram (b) demonstrates both central and peripheral vascularity. [Reproduced with permission from Indian Journal of Endocrinology and Metabolism.]

size <1 cm, width > length, presence of hypoechoic halo around the nodule (fibrous capsule or compressed thyroid tissue) and coarse/curvilinear calcification are

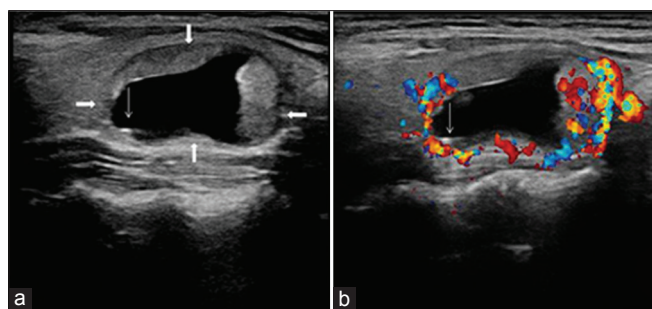


**Figure 3:** Benign thyroid adenoma in a 42-year-old female patient. Transverse gray-scale ultrasound neck (a) shows a large well circumscribed oval shaped (width>length), hyperechoic nodule in a thyroid lobe. The lesion has slight heterogeneous appearance due to presence of few tiny cystic spaces/clefts. A thin, hypoechoic capsule (arrow) is noted peripherally. Color Doppler image (b) demonstrates both central and peripheral vascularity with characteristic "spoke-and-wheel-like" appearance

less specific but may be useful ancillary signs.<sup>[1,5]</sup> "Ring down" or "comet-tail" artifact or sign is typical of benign cystic colloid nodule [Figure 5].<sup>[11]</sup> Perinodular flow or spoke-and-wheel-like appearance of vessels on color Doppler examination is characteristic of a benign thyroid nodule [Figures 3 and 4]. However, this flow pattern may also be seen in thyroid malignancy. A complete avascular nodule is very unlikely to be malignant.<sup>[1,10]</sup>

Histologically, malignant tumors of the thyroid are classified as papillary carcinoma (60-80%), follicular carcinoma (20-25%), medullary carcinoma (4-5%), anaplastic carcinoma (3-10%), lymphoma (5%) and metastases.<sup>[12]</sup> The overall sensitivity of thyroid ultrasound for diagnosing a malignant nodule is 83.3%.<sup>[5]</sup> USG features predictive of malignant nodules include presence of microcalcifications (<2 mm), local invasion, lymph node metastases, marked hypoechoogenicity, irregular margins, solid composition, absence of a hypoechoic halo around the nodule, size >1 cm, taller-than-wide-shape, and an intra nodular vascularity.<sup>[10]</sup> Multiplicity of the nodule is not an indicator of benignity. The incidence of malignancy is same in solitary nodules as it is in multiple nodules. Interval growth of nodules is a non-specific characteristic. Microcalcifications are most commonly found in papillary and

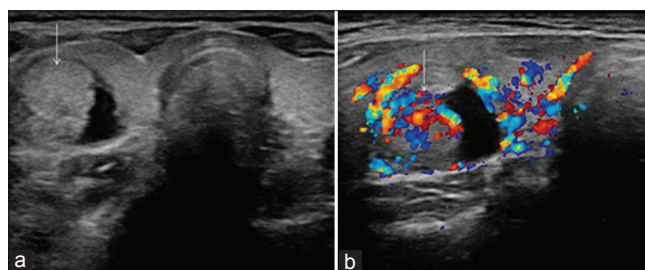




**Figure 5:** Benign cystic colloid nodule in a 55-year-old female patient. Transverse sonogram neck (a) reveals a well-circumscribed right-sided cystic nodule with solid peripheral component and 'ring down' artifact (thin arrow). The lesion demonstrates a thin hypoechoic rim (thick arrows) and posterior acoustic enhancement. Color Doppler image (b) demonstrates vascularity in the solid peripheral component. (Reproduced with permission from Indian Journal of Endocrinology and Metabolism)

medullary carcinoma thyroid and in their metastases (lymph node or hepatic). On USG, microcalcifications appear as punctuate hyperechoic foci with or without posterior acoustic shadowing. Rarely, microcalcifications can be found in follicular and anaplastic thyroid carcinomas and certain benign lesions like follicular adenoma, multinodular goitre and Hashimoto's thyroiditis.<sup>[10,12]</sup> Local invasion of adjacent structures and metastases to regional cervical lymph nodes are highly specific signs of thyroid malignancy. They occur more frequently in medullary carcinoma (50% cases) than papillary carcinoma (40% cases). Although patients with thyroid carcinoma may present with multiple level nodal disease, the anterolateral group (level II, III and IV) have greatest risk of metastatic disease. US neck plays an integral role in the management of cervical metastases from thyroid carcinoma (ranging from selective removal to a comprehensive neck dissection) by evaluating nodal metastases with respect to node level.<sup>[13]</sup> Anaplastic thyroid carcinoma and lymphoma are highly aggressive tumors, early and extensive local invasion is common with these tumors. Lymph node metastasis is rare in follicular thyroid carcinoma, even in highly invasive cases.<sup>[5,10,12]</sup> The most common pattern of vascularity in thyroid malignancy is marked intrinsic hyper vascularity. On color Doppler examination, more flow is demonstrated in the central portion of the tumor than in the surrounding thyroid parenchyma [Figure 6]. Increased vascularity with distortion of sinus fat is seen within the metastatic lymph nodes. Thyroid lymphomas are hypo-vascular with chaotic vessels; however, neck vessel encasement may be present.<sup>[1,10]</sup>

Metastases to the thyroid gland are infrequent. The main primary tumors spreading to the thyroid gland are malignant melanoma (39% of cases), breast carcinoma (21% of cases) and renal cell carcinoma (10% of cases). Sonographically, metastases present as a solitary or multiple hypoechoic homogeneous mass(es) without calcification.<sup>[5,10,12]</sup>



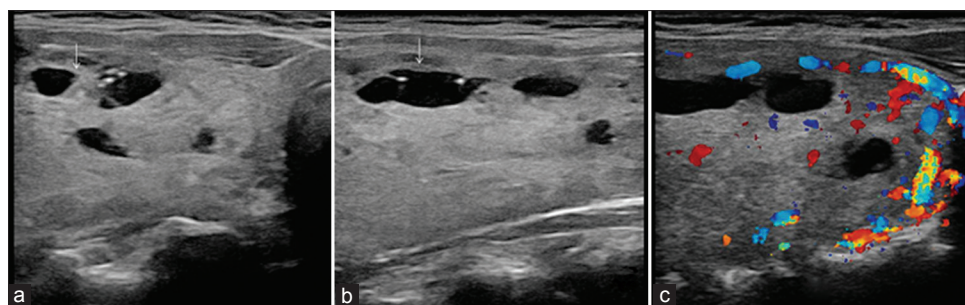
**Figure 6:** Malignant thyroid nodule. Hürthle cell (follicular) carcinoma in a 60-year-old woman. Transverse sonogram (a) of right lobe of the thyroid shows a partially cystic tumor with solid internal nodule (arrow) and thick walls. Color Doppler sonogram (b) depicts increased vascularity in solid parts of the tumor (arrow)

Thyroid nodule(s) with suspicious USG features should be investigated further with FNA biopsy. Moreover, the work-up of asymptomatic thyroid nodules (incidentalomas) must be weighed against high prevalence of benign thyroid nodules and low mortality rate from small thyroid carcinomas.

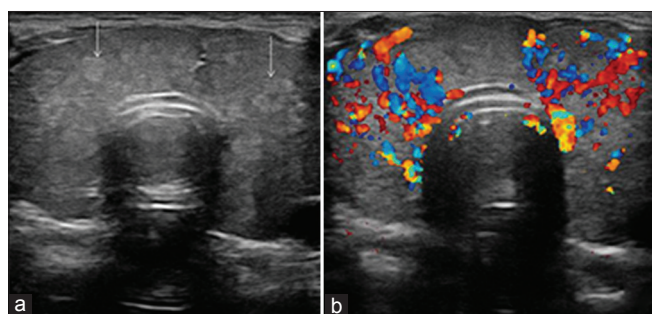
## DIFFUSE THYROID DISEASES

The common conditions that present as diffuse enlargement of the thyroid gland include multinodular goitre, Hashimoto's (lymphocytic) thyroiditis, de-Quervain's subacute thyroiditis and Graves' disease. The sonographic features of these processes may be similar but they have different biochemical profile and clinical presentations. Hence, in these conditions, ultrasound findings should be viewed in relation to clinical and biochemical status of the patient.

Multinodular goitre (MNG) is the commonest cause of diffuse asymmetric enlargement of the thyroid gland. Females between 35-50 years of age are most commonly affected. Histologically, colloid [Figure 7] or adenomatous [Figure 8] form of MNG is common. The ultrasound diagnosis rests on the finding of multiple nodules within a diffusely enlarged gland. A diffusely enlarged thyroid gland with multiple nodules of similar US appearance and with no normal intervening parenchyma is highly suggestive of benignity, thereby making FNA biopsy unnecessary.<sup>[10]</sup> Most of the nodules are iso- or hyper-echoic in nature; when enlarged provide heterogeneous echo pattern to the gland. These goitrous nodules often undergo degenerative changes that correspond to their USG appearances: cystic degeneration gives anechoic appearance to the nodule, hemorrhage or infection within the cyst is seen as moving internal echoes/septations, colloidal degeneration produces comet-tail artifact, while dystrophic calcification is often coarse or curvilinear. Vascular compression due to follicular hyperplasia leads to focal ischemia, necrosis



**Figure 7:** Colloid multinodular goitre in a 50-year-old female patient. Transverse (a) and longitudinal (b) gray-scale ultrasound neck images reveal enlarged thyroid gland having multiple hyperechoic colloid nodules with internal cystic areas (arrows) showing 'ring down' sign. Color Doppler image (c) shows increased peripheral vascularity, with some intra goitrous vascularity



**Figure 8:** Adenomatous multinodular goitre in a 48-year-old patient with thyrotoxicosis. Transverse gray-scale ultrasound neck (a) shows diffuse enlargement of thyroid gland with multiple small (~5 mm size) echogenic nodules involving both the lobes and isthmus (arrows), with no normal-appearing intervening parenchyma. Color Doppler sonogram (b) demonstrates diffusely increased parenchymal vascularity. FNA biopsy confirmed the diagnosis of adenomatous multinodular goitre. However, it should be noted that FNA biopsy is not likely to be necessary in a diffusely enlarged thyroid gland with multiple nodules of similar US appearance and no normal intervening parenchyma

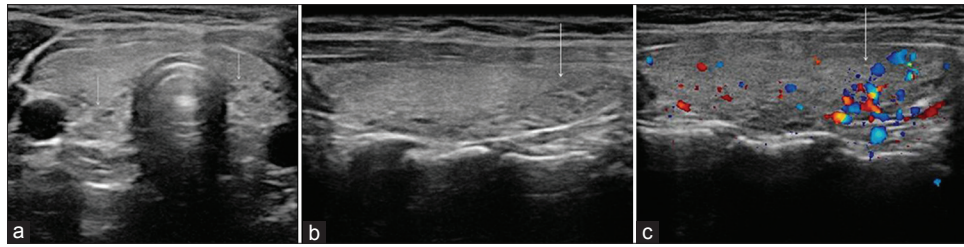
and inflammatory change. The assessment of nodule vascularity is very useful in differentiating MNG from multifocal carcinoma. Nodule with intrinsic vascularity and other features of malignancy can be targeted for biopsy, in preference to other nodules.<sup>[10,11]</sup>

Graves' disease (thyrotoxicosis) is an autoimmune disease characterized by thyrotoxicosis. Females between 20 and 50 years are most commonly affected. On gray-scale USG, thyroid is diffusely enlarged (2-3 times its normal size), hypoechoic and heterogeneous. Color flow imaging reveals a spectacular "thyroid inferno" with marked hyper vascularity. This pattern demonstrates extensive intra-thyroid flow both in systole and diastole. In contrast to Hashimoto's thyroiditis, return of normal thyroid appearance is possible at the time of remission. The ultrasound picture of Graves' disease may be indistinguishable from Hashimoto's thyroiditis and de Quervain's thyroiditis; however, clinical picture varies significantly between these three conditions.<sup>[14,15]</sup>

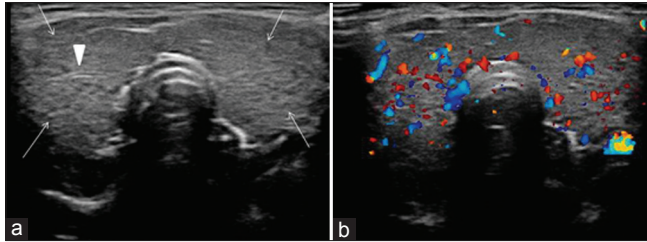
Hashimoto's thyroiditis (chronic lymphocytic thyroiditis) is an autoimmune disorder leading to destruction of the gland

and hypothyroidism. It occurs predominantly in females over 40 years of age. Painless, diffuse enlargement of thyroid gland is the most common clinical presentation. Clinically, Hashimoto's thyroiditis may present with formation of goitre with or without disturbance of thyroid function. Children with hypothyroidism usually have growth failure and delayed puberty. Diagnosis of Hashimoto's thyroiditis is confirmed by demonstration of serum thyroid antibodies and antithyroglobulin antibodies. The characteristic US appearance [Figures 9 and 10] is focal or diffuse glandular enlargement with coarse, heterogeneous and hypoechoic parenchymal echo pattern. Presence of multiple discrete hypoechoic micronodules (1-6 mm size) is strongly suggestive of chronic thyroiditis. Fine echogenic fibrous septae may produce a pseudolobulated appearance of the parenchyma. Color Doppler may demonstrate slight to markedly increased vascularity of the thyroid parenchyma. Increased vascularity seems to be associated with hypothyroidism, likely due to trophic stimulation of thyroid-stimulating hormone. Small atrophic gland represents end stage Hashimoto's thyroiditis. Occasionally, nodular form of Hashimoto's thyroiditis may occur; within a sonographic background of diffuse Hashimoto's thyroiditis or within normal thyroid parenchyma. Both benign and malignant nodules are known to co-exist within a background of diffuse Hashimoto's thyroiditis; on ultrasound, hyperechoic nodules are more likely to be benign, whereas hypoechoic nodules are more likely to be malignant [Figures 11 and 12]. However, a PET scan or FNAC may be required to differentiate them. The abnormal thyroid ultrasound picture in Hashimoto's thyroiditis never improves and remains unchanged for rest of the patient's life. Hashimoto's thyroiditis is associated with an increased risk of thyroid malignancies like follicular or papillary carcinoma and lymphoma.<sup>[13,16-18]</sup> Moreover, in patients of Hashimoto's thyroiditis, USG examination may reveal presence of perithyroidal satellite lymph nodes, especially the "Delphian" node just cephalad to the isthmus [Figure 13]. These perithyroidal lymph nodes are extremely useful in diagnosis of the thyroiditis when correlated with USG, clinical and laboratory findings.

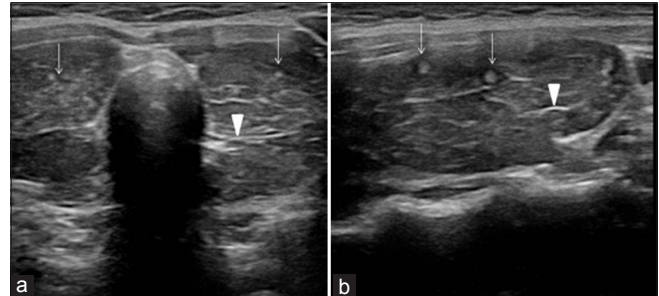




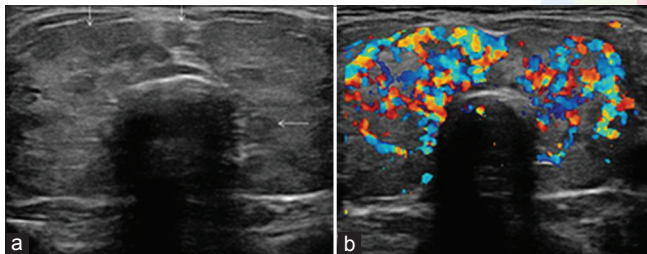
**Figure 9:** Focal Hashimoto's thyroiditis in a 35-year-old female patient, who presented with features of hypothyroidism and had anti-thyroid antibodies positive for the disease. Transverse gray-scale ultrasound neck (a) demonstrates ill-defined heterogeneous hypoechoic areas localized to postero-inferior aspect of thyroid lobes bilaterally (arrows). Longitudinal scan (b) left lobe thyroid (of same patient) clearly depicts the abnormal area which also shows increased vascularity on color Doppler sonogram (c)



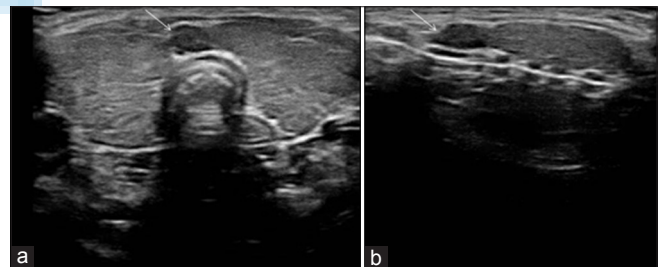
**Figure 10:** Diffuse Hashimoto's thyroiditis in a 35-year-old female patient, who presented with features of hypothyroidism and had anti-thyroid antibodies positive for the disease. Transverse gray-scale ultrasound neck (a) demonstrates diffuse enlargement of thyroid gland with heterogeneous echotexture. Multiple tiny and discrete hypoechoic nodules (micronodules, arrows) and few linear echogenic septae (arrowhead) are also noted. Color Doppler sonogram (b) demonstrates mildly increased parenchymal vascularity



**Figure 11:** Nodular Hashimoto's thyroiditis (multiple echogenic nodules in sonographic background of diffuse Hashimoto's thyroiditis) in a 40-year-old female patient, who presented with hypothyroidism and had anti-thyroid antibodies positive for the disease. Transverse (a) and longitudinal (b) ultrasound neck images show diffusely enlarged and hypoechoic thyroid gland, with linear echogenic fibrous septae (arrowheads), and multiple small and discrete echogenic parenchymal nodules (arrows). Note, perinodular hypoechoic halo associated with few nodules in image b. Color Doppler imaging demonstrated increased parenchymal vascularity (image not shown). FNAC proved Hashimoto's thyroiditis



**Figure 12:** Nodular Hashimoto's thyroiditis (multiple hypoechoic nodules in sonographic background of diffuse Hashimoto's thyroiditis) in a 37-year-old male patient who presented with hypothyroidism and had anti-thyroid antibodies positive for the disease. Transverse gray-scale ultrasound neck (a) shows diffusely enlarged thyroid gland with multiple (>5) small and discrete hypoechoic nodules involving both the lobes and isthmus (arrows). Color Doppler image (b) demonstrates diffusely increased parenchymal vascularity. It should be noted that both benign and malignant nodules can co-exist within Hashimoto's thyroiditis; hence, FNAC may be required to differentiate them



**Figure 13:** Diffuse Hashimoto's thyroiditis (with cervical lymphadenopathy) in a 37-year-old female patient, who presented with features of hypothyroidism and anti-thyroid antibodies positive for the disease. Transverse (a) and longitudinal (b) gray-scale ultrasound neck images demonstrate the sonographic features of diffuse Hashimoto's thyroiditis, associated with a cervical lymph node just cephalad to the isthmus (the "Delphian" lymph node) (arrow). FNAC of the node revealed reactionary/inflammatory changes. The lymph node may be confused with thyroid isthmus nodule

However, it should be kept in mind that these lymph nodes may also correspond to underlying malignant processes, like thyroid malignancy and lymphoma, in patients with Hashimoto's thyroiditis. In doubtful cases, FNA biopsy may be required to differentiate between benign (reactionary/inflammatory origin) and malignant lymph nodes.<sup>[19]</sup>

De Quervain's thyroiditis (subacute granulomatous thyroiditis) characteristically presents with painful swelling

in lower neck, fever and constitutional symptoms, typically following a viral illness. There may be features of thyrotoxicosis or hypothyroidism depending on phase of the illness. Initially there is thyrotoxicosis, followed by hypothyroidism. USG examination shows characteristic focal hypoechoic areas (map like) and enlargement of one or both thyroid lobes. Level VI chain lymph nodes (pre-tracheal,

the preferential site of thyroid drainage) are found to be enlarged in majority of patients.<sup>[19]</sup> Color Doppler sonography shows decrease or absent blood flow within abnormal map-like hypoechoic areas. Complete recovery is characteristic and occurs in weeks to months. In recovery phase, thyroid appearance returns to normal.<sup>[14,20]</sup>

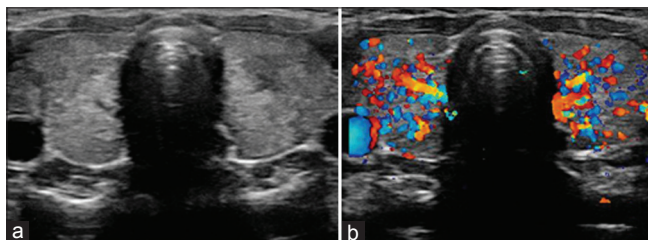
Acute thyroiditis (suppurative/infectious thyroiditis) is rare and occurs due to suppurative infection of the thyroid. In children and adults, the most common cause is infection of pyriform sinus fistula (a congenital branchial pouch abnormality). In elderly, long standing goitre and degeneration in thyroid malignancy are risk factors. Clinically, patient presents with acute onset fever, thyroid pain, asymmetric swelling of the gland (predominantly left sided) and regional lymphadenopathy (level VI cervical chain lymph nodes). On USG [Figure 14], the involved lobe appears heterogeneous and hypoechoic. Abscess and cyst formation may be seen. Rarely, retropharyngeal abscess, tracheal obstruction, jugular vein thrombosis and mediastinitis may complicate acute thyroiditis.<sup>[14]</sup>

Riedel's thyroiditis (chronic fibrous thyroiditis/invasive fibrous thyroiditis) is the rarest type of inflammatory thyroid disease. The thyroid gland is gradually replaced by fibrous connective tissue and becomes extremely hard. It may encase the adjacent vessels or may compress, displace or deform shape of the trachea. On ultrasound, Riedel's thyroiditis may present as a diffuse hypoechoic process with ill-defined margins and marked fibrosis.<sup>[14,21]</sup>

## DIAGNOSTIC PITFALLS

Major diagnostic pitfalls of thyroid ultrasound include

- i Cystic components of thyroid malignancies may be mistaken for benign cyst or cystic degeneration in a benign nodule. A careful ultrasound assessment to demonstrate solid component with vascularity or solid excrescence with microcalcifications will be of help in differentiating these lesions.
- ii Cystic or calcified lymph node metastases adjacent to



**Figure 14:** Acute thyroiditis in a 12-year-old female patient, who presented with acute onset fever, neck pain and swelling. Transverse gray-scale ultrasound neck (a) shows bilaterally enlarged thyroid lobes with heterogeneous echo pattern. Color Doppler sonogram (b) demonstrates increased parenchymal vascularity in both lobes of the thyroid

the thyroid gland may be mistaken for benign nodule in multinodular thyroid disease. Incomplete rim of thyroid parenchyma around the mass and lack of movement of the mass with the thyroid gland during swallowing favors extrathyroid lymph nodal metastasis. Cystic metastatic nodes are more common in papillary carcinoma thyroid, while calcified metastatic nodes are found both in papillary and medullary carcinoma thyroid.

- iii Diffusely infiltrative hyper vascular thyroid carcinoma like papillary or follicular carcinoma may be mistaken for autoimmune thyroid disease (such as Graves' disease or Hashimoto's thyroiditis); similarly multifocal carcinoma may be mistaken for benign multinodular goitre. As described earlier, diffuse thyroid enlargement with multiple nodules of similar US appearance and with no normal intervening parenchyma is highly suggestive of benignity. US features that suggest malignancy include irregular or nodular enlargement of the thyroid gland, local invasion and nodal metastases. Co-existing autoimmune thyroid disease and thyroid carcinoma can further complicate the situation.<sup>[5,10,12]</sup>

## THERAPEUTIC APPLICATION

US-guided percutaneous ethanol injection (EPI) is used for sclerosation of autonomous and toxic thyroid adenomas. Post-injection follow-up ultrasound scan demonstrates significant reduction in nodule size on gray-scale imaging, and marked reduction or complete absence of intra nodular flow on color and power Doppler examination.<sup>[22]</sup> Periodic neck ultrasound is the most sensitive method for detecting recurrence of thyroid carcinomas after thyroidectomy.<sup>[23]</sup>

## ADVANCED ULTRASOUND TECHNIQUES IN THYROID IMAGING

Ultrasound elastography is a dynamic technique that estimates stiffness of tissues by measuring the degree of distortion under external pressure. Thyroid gland elastography is used to study hardness/elasticity of the thyroid nodule to differentiate malignant from benign lesions. A benign nodule is softer and deforms more easily, whereas the malignant nodule is harder and deforms less when compressed by ultrasound probe. The elastography technique utilizes external compression to differentiate malignant thyroid nodules from benign lesions. It determines the amount of tissue displacement at various depths, by assessing the ultrasound signals reflected from the tissues before and after compression. Dedicated software then provides an accurate measurement of tissue distortion and displays it visually as an elastographic

image. The elastographic image (elastogram) displayed over the B-mode image in a color scale, indicates local tissue elasticity as (i) very soft in blue color for tissue with greatest elastic strain and (ii) very hard in red color for tissue with no strain. Real-time shear elastography is a latest technique; that characterizes and quantifies tissue stiffness better than conventional elastography.<sup>[24,25]</sup> Cystic lesions and calcified nodules are excluded from US elastographic evaluation. US elastography helps in characterizing a cytologically indeterminate nodule as malignant or benign with high accuracy that is almost comparable to FNAC and obviates the need of unnecessary FNA examination. The major limitation of US elastography is that it cannot assess the lesions which are not surrounded by adequate normal tissue.<sup>[2,26]</sup>

Contrast-enhanced ultrasound (CE-US) is a newly developed technique that helps in characterizing a thyroid nodule. On CE-US, enhancement patterns are different in benign and malignant lesions. Ring enhancement is predictive of benign lesions, whereas heterogeneous enhancement is helpful for detecting malignant lesions. However, overlapping findings seem to limit the potential of this technique in the characterization of thyroid nodules.<sup>[27]</sup> Use of specific contrast (e.g. Sono Vue) and pulse inversion harmonic imaging further improves the efficacy of ultrasound in diagnosing a malignant thyroid nodule.<sup>[2,3]</sup>

## CURRENT STATUS OF US ELASTOGRAPHY AND CE-USG IN CHARACTERISATION OF THYROID NODULES

Several studies have been conducted to evaluate the role of ultrasound using elastography and contrast agent in the characterisation of thyroid nodules.

A study (done on 23 thyroid nodules) was conducted by FS Ferrari *et al.* in 2008, to differentiate benign from malignant thyroid nodule, using both elastography and CE-US. Elastography yielded a sensitivity of 88%, specificity of 78%, positive predictive value (PPV) of 71%, negative predictive value (NPV) of 91% and diagnostic accuracy (DA) of 82%; and CE-US yielded a sensitivity of 100%, specificity of 71%, PPV of 69%, NPV 100% and DA of 83%.<sup>[28]</sup>

Another study (sample size 90) was done by Y Hong *et al.* in 2009 to evaluate the diagnostic utility of real-time ultrasound elastography in differentiating benign from malignant thyroid nodules. According to this study, elastography yielded a sensitivity of 88%, specificity of 90%, PPV of 81% and NPV 93%.<sup>[29]</sup>

A recent study (done on 703 thyroid nodules) published by

Moon *et al.* in 2012 evaluated the diagnostic performance of gray-scale US and elastography in differentiating solid thyroid nodules. According to the study, the sensitivity and NPV for differentiating benign from malignant thyroid nodules on gray scale US are 91% and 94.7% respectively, and on US elastography are 65.4% and 79.1% respectively. They concluded that elastography alone or in combination with gray scale US is not a useful tool in differentiating benign from malignant thyroid nodules.<sup>[30]</sup>

Another study (sample size 72) has been done recently by M Giusti *et al.* in 2012, in which they have evaluated the role of ultrasound, elastography and CE-US in screening of thyroid nodules. They found that the ultrasound score showed high specificity and PPV when compared with elastography and CE-US. Both elastography and CE-US were expensive, time consuming and of limited utility in selecting patients for thyroidectomy.<sup>[31]</sup>

In short, some studies show very high sensitivity and specificity of US elastography; in the range of 85-90%. On the contrary, there are studies which show its sensitivity as low as 65% and less (compare from the sensitivity of gray-scale US which is in the range of 90 to 95%).

Thus, although elastography and CE-US appear promising imaging techniques, they need to be standardized. At present, they seem to be expensive, time consuming and of limited utility in selecting patients for surgery. Larger prospective studies are needed to establish the diagnostic accuracy and cost effectiveness of these techniques over conventional gray scale and color Doppler imaging.

## CONCLUSION

High-resolution USG has improved in the past few years and has become a very valuable diagnostic tool in the evaluation of thyroid diseases. Recent advances in thyroid ultrasound have further improved the diagnostic accuracy. It is the imaging modality of choice for evaluating thyroid masses in children and pregnant females. Real time USG also helps to guide the diagnostic and therapeutic interventional procedures in various thyroid diseases.

## REFERENCES

1. Solbiati L, Charboneau JW, Osti V, James EM, Hay ID. The thyroid gland. In: Rumack CM, Wilson SR, Charboneau JW, editors. Diagnostic Ultrasound. 3<sup>rd</sup> ed., Vol. 1. St. Louis, Missouri: Elsevier Mosby; 2005. p. 735-70.
2. Chaudhary V, Bano S. Imaging of the thyroid: Recent advances. Indian J Endocrinol Metab 2012;16:371-6.
3. Gharib H, Papini E, Valcavi R, Baskin HJ, Crescenzi A, Dottorini ME,



- et al.* American Association of Clinical Endocrinologists and Associazione Medici Endocrinologi medical guidelines for clinical practice for the diagnosis and management of thyroid nodules. *Endocr Pract* 2006;12:63-102.
4. Baskin HJ. Ultrasound of thyroid nodules. In: Baskin HJ, editor. *Thyroid Ultrasound and Ultrasound-guided FNA Biopsy*. Boston: Kluwer Academic Publisher; 2007. p. 71-86.
  5. Moon WJ, Jung SL, Lee JH, Na DG, Baek JH, Lee YH, *et al.* Benign and malignant thyroid nodules: US differentiation-multicenter retrospective study. *Radiology* 2008;247:762-70.
  6. Ghervan C. Thyroid and parathyroid ultrasound. *Med Ultrason* 2011;13:80-4.
  7. Kaplan EL, Shukla M, Hara H, Ito K. Developmental abnormalities of the thyroid. In: De Groot LJ, editor. *Endocrinology*. Philadelphia: Saunders; 1994. p. 893-9.
  8. Larsen WJ. Development of the head and the neck. In: Larsen WJ, editor. *Human Embryology*. New York: Churchill Livingstone; 1993. p. 335-9.
  9. Léger J, Marinovic D, Garel C, Bonaïti-Pellié C, Polak M, Czernichow P. Thyroid developmental anomalies in first degree relatives of children with congenital hypothyroidism. *J Clin Endocrinol Metab* 2002;87:575-80.
  10. Hoang JK, Lee WK, Lee M, Johnson D, Farrell S. US Features of thyroid malignancy: Pearls and pitfalls. *Radiographics* 2007;27:847-60.
  11. Ahuja A, Chick W, King W, Metreweli C. Clinical significance of the comet-tail artifact in thyroid ultrasound. *J Clin Ultrasound* 1996;24:129-33.
  12. Brkljacic B, Cuk V, Tomić-Brzac H, Bence-Zigman Z, Delić-Brkljacic D, Drinković I. Ultrasonic evaluation of benign and malignant nodules in echographically multinodular thyroids. *J Clin Ultrasound* 1994;22:71-6.
  13. Sivanandan R, Soo KC. Pattern of cervical lymph node metastases from papillary carcinoma of the thyroid. *Br J Surg* 2001;88:1241-4.
  14. Ruchala M, Szczepanek E. Thyroid ultrasound-a piece of cake? *Endokrynol Pol* 2010;61:330-44.
  15. Ralls PW, Mayekawa DS, Lee KP, Colletti PM, Radin DR, Boswell WD, *et al.* Color-flow Doppler sonography in Graves disease: "Thyroid inferno". *AJR Am J Roentgenol* 1988;150:781-4.
  16. Yeh HC, Futterweit W, Gilbert P. Micronodulation: Ultrasonographic sign of Hashimoto thyroiditis. *J Ultrasound Med* 1996;15:813-9.
  17. Anderson L, Middleton WD, Teefey SA, Reading CC, Langer JE, Desser T, *et al.* Hashimoto thyroiditis: Part 1, sonographic analysis of the nodular form of Hashimoto thyroiditis. *AJR Am J Roentgenol* 2010;195:208-15.
  18. Anderson L, Middleton WD, Teefey SA, Reading CC, Langer JE, Desser T, *et al.* Hashimoto thyroiditis: Part 2, sonographic analysis of benign and malignant nodules in patients with diffuse Hashimoto thyroiditis. *AJR Am J Roentgenol* 2010;195:216-22.
  19. Yamashiro I, de Cassio Saito O, Chammas MC, Cerri GG. Ultrasound findings in thyroiditis. *Radiol Bras* 2007;40:75-9.
  20. Kunz A, Blank W, Braun B. De Quervain's subacute thyroiditis – color Doppler sonography findings. *Ultraschall Med* 2005;26:102-6.
  21. Ozbayrak M, Kantarci F, Olgun DC, Akman C, Mihmanli I, Kadioglu P. Riedel thyroiditis associated with massive neck fibrosis. *J Ultrasound Med* 2009;28:267-71.
  22. Brkljacic B, Ivanac G, Cikara I, Bozikov V. Percutaneous ultrasound-guided ethanol injection treatment of thyroid toxic and autonomous adenoma: result and long-term follow-up. *J Ultrasound Med* 2009;28:S83.
  23. Schlumberger M, Berg G, Cohen O, Duntas L, Jamar F, Jarzab B, *et al.* Follow-up of low-risk patients with differentiated thyroid carcinoma: A European perspective. *Eur J Endocrinol* 2004;150:105-12.
  24. Hall TJ. AAPM/RSNA physics tutorial for residents: topics in US: beyond the basics: elasticity imaging with US. *Radiographics* 2003;23:1657-71.
  25. Friedrich-Rust M, Sperber A, Holzer K, Diener J, Grünwald F, Badenhoop K, *et al.* Real-time elastography and contrast-enhanced ultrasound for the assessment of thyroid nodules. *Exp Clin Endocrinol Diabetes* 2010;118:602-9.
  26. Mansor M, Okasha H, Esmat S, Hashem AM, Attia KA, El-din Hussein H. Role of ultrasound elastography in prediction of malignancy in thyroid nodules. *Endocr Res* 2012;37:67-77.
  27. Zhang B, Jiang YX, Liu JB, Yang M, Dai Q, Zhu QL, *et al.* Utility of contrast-enhanced ultrasound for evaluation of thyroid nodules. *Thyroid* 2010;20:51-7.
  28. Ferrari FS, Megliola A, Scorzelli A, Guarino E, Pacini F. Ultrasound examination using contrast agent and elastography in the evaluation of single thyroid nodules: Preliminary results. *Journal of Ultrasound* 2008;11:47-54.
  29. Hong Y, Liu X, Li Z, Zhang X, Chen M, Luo Z. Real-time ultrasound elastography in the differential diagnosis of benign and malignant thyroid nodules. *J Ultrasound Med* 2009;28:861-7.
  30. Moon HJ, Sung JM, Kim EK, Yoon JH, Youk JH, Kwak JY. Diagnostic performance of gray-scale US and elastography in solid thyroid nodules. *Radiology* 2012;262:1002-13.
  31. Giusti M, Orlandi D, Melle G, Massa B, Silvestri E, Minuto F. Is there a real diagnostic impact of the elastography and contrast enhanced ultrasonography in the management of thyroid nodules? *J Zhejiang Univ-Sci B (Biomed and Biotechnol)*. In press 2012.

**Cite this article as:** Chaudhary V, Bano S. Thyroid ultrasound. *Indian J Endocr Metab* 2013;17:219-27.

**Source of Support:** Nil, **Conflict of Interest:** None declared.